

# EUROPEAN JOURNAL OF CARDIO-THORACIC SURGERY

## **Transaxillary approach in thoracic outlet syndrome: the importance of resection of the first-rib**

Serdar Han, Erkan Yildirim, Koray Dural, Kanat Özisik, Rasih Yazkan and Ünal Sakinci  
*Eur J Cardiothorac Surg* 2003;24:428-433  
DOI: 10.1016/S1010-7940(03)00333-6

**This information is current as of July 14, 2009**

The online version of this article, along with updated information and services, is located on the World Wide Web at:

<http://ejcts.ctsnetjournals.org/cgi/content/full/24/3/428>

The European Journal of Cardio-thoracic Surgery is the official Journal of the European Association for Cardio-thoracic Surgery and the European Society of Thoracic Surgeons. Copyright © 2003 by European Association for Cardio-Thoracic Surgery. Published by Elsevier. All rights reserved. Print ISSN: 1010-7940.

## Transaxillary approach in thoracic outlet syndrome: the importance of resection of the first-rib

Serdar Han\*, Erkan Yildirim, Koray Dural, Kanat Özisik, Rasih Yazkan, Ünal Sakinci

Ankara Numune Education and Research Hospital, Thoracic Surgery Department, Ankara, Turkey

Received 5 March 2003; received in revised form 3 May 2003; accepted 12 May 2003

### Abstract

**Objective:** The aim of this study was to analyze the transaxillary surgical approach and results of thoracic outlet cases in our clinic in the light of the recent literature data. **Methods:** Between 1996 and 2002 a series of 35 cases diagnosed as thoracic outlet syndrome (TOS) hospitalized and surgically treated in our clinic have been studied retrospectively. **Results:** Twenty-six of our cases were females (75%) and the mean age was  $25 \pm 1$  (17–40 years). The most important symptom was localized pain in the arm. In 90% of the cases the Adson, hyperabduction and abduction external rotation (AER) tests were positive. There was paresthesia in 30 cases (85%), atrophy in 3 cases (10%), and cyanosis in 6 cases (20%). Preoperative electromyogram (EMG) was demonstrated as 56.7 m/s (50–65) and postoperative EMG was demonstrated as 65.1 m/s (60–71). Postoperative EMG values were significantly higher than the preoperative EMG values ( $p < 0.001$ ). All patients were operated using the transaxillary approach. A total number of 40 operations were performed. Upon radiological investigation ( $n = 17$ ) 50% of the patients were found to have cervical ribs. In 30 cases (85%) the results were very good and in four cases (12%) good, and in one case (3%) the results were bad. There was no recurrence and reoperation in the long term follow-up. **Conclusion:** Careful patient history and physical examination should be done by a team, which consists of thoracic surgeon, physical therapy specialist, and a neurologist. Total resection of the first-rib with periosteally should be preferred in all of these cases with accompanying pathologies such as cervical rib, fibrous ligaments, and scalenius muscles. The transaxillary approach has provided a good exposure for the resection of cervical ribs, the first-rib and excision of fibrous ligaments and scalenius muscle by a perfect cosmetic result. All the patients should be encouraged for 2 months of physical exercises starting from early postoperative period.

© 2003 Elsevier B.V. All rights reserved.

**Keywords:** Thoracic outlet syndrome; Surgery; Transaxillary approach

### 1. Introduction

Thoracic outlet is the area from the outer edge of the first-rib laterally to the upper medial mediastinum, continuing cephalad to the level of the fifth cervical nerve root. The middle and anterior scalene muscles, the five primary nerves and three trunks that comprise the brachial plexus, the phrenic nerve, long thoracic, suprascapular, and dorsal scapular nerves, the stellate ganglion, the subclavian artery and vein, the thoracic duct, scalene lymph nodes, and the apex of the lung lie in this anatomic space. For surgical purposes, it should be divided into an upper part, best

reached by the supraclavicular approach, and a lower part, best reached using the transaxillary approach [1].

Thoracic outlet syndrome (TOS) is a clinical phenomenon resulting from compression of neurovascular structures at the superior aperture of the thorax which presents with varying symptoms. The term TOS was used for the first time in the literature by Rob and Standeven in 1958 [2]. This clinical picture has also been named as costoclavicular syndrome, cervical rib syndrome, scalenius anticus syndrome, subclavius tendon syndrome or musculus pectoralis major syndrome by various authors [3].

For more than 100 years various surgical treatments for TOS, such as resection of the cervical rib, resection of the clavicle, resection of the first-rib or resection of the tendon of scalene or pectoral muscles by either posterior, cervical or supraclavicular approaches have been tried [3]. Especially after the researches in the second half of the 20th

\* Corresponding author. Mamak Caddesi 43/11 Demirlibahce, 06340 Ankara, Turkey. Tel.: +90-312-3633074; fax: +90-312-3103460.  
E-mail address: [serdarhan1@yahoo.com](mailto:serdarhan1@yahoo.com) (S. Han).

century it has been shown that the first-rib is responsible for the neurovascular compression in TOS. Because of this reason, Clagett used the resection of the first-rib by posterior toracoplasty incision in 1962 [4]. This method has not been adopted widely because it requires a wide incision and a lengthy operation. Ross had, for the first time, used the transaxillary approach to excise the first-rib in 1966 and this method has been widely accepted and became the most widely used method in the recent years [5]. There are two operative procedures, the transaxillary approach for first-rib resection or a supraclavicular approach for anterior and middle scalenectomies, with or without first-rib resection for the surgical treatment of TOS [6].

## 2. Patients and methods

### 2.1. Symptoms

In our clinic, 35 cases with symptoms suggestive of TOS have been studied retrospectively. Symptoms were as follows:

Related to acute or chronic neurologic compression: localized pain, paresthesia, numbness.

Related to vascular compression (arterial or venous): supraclavicular or infraclavicular bruit, absent radial pulse, pulsating paraclavicular mass, coldness, cyanosis, persistent rubor, pallor, venous congestion, edema.

### 2.2. Clinical evaluation

Many clinical tests (Adson's, Roos's, Halsted, Wright and Thumb print tests, etc.), radiographic, and electrodiagnostic tests have been described to assist in the diagnosis of TOS, although none has been universally accepted as a standard one. The physical examination was performed in an order as indicated below:

Adson's test has the patient turn his or her head toward the affected side, extend the neck, and then inspire deeply. Obliteration of the radial pulse suggests compression. This test is often modified by having the patient rotate the head to the unaffected side [7].

Costoclavicular or Halsted test, the patient holds the shoulders backwards and in the downward direction (military position). Obliteration of the radial pulse would be considered a positive diagnostic test [7].

Wright described a similar hyperabduction test in which the shoulder is hyperabducted to 180° and the elbow is flexed [7].

### 2.3. Investigations

In all our cases complete blood counts, biochemical tests were routinely performed. Posteroanterior chest X-rays and two sided cervical X-rays were useful in identifying bone abnormalities. Plain radiographs revealed cervical ribs, degenerative changes in the cervical spine, and large C7 transverse processes that can compress the brachial plexus. Radiographic evaluation was most useful in identifying other pathologies that may be causing patient symptomatology rather than establishing the diagnosis of TOS. For vascular compression, upper extremity venous and arterial doppler ultrasonographic examinations were performed. For neurological compression, upper extremity erb-axilla electromyoneurographies were obtained preoperatively and postoperatively.

### 2.4. Final diagnosis and therapeutic options

The results have been examined by a team consisting of a thoracic surgeon, physical therapy specialist and a neurologist in order to make a differential diagnosis to eliminate cervical discopathy, carpal tunnel syndrome, cubital tunnel syndrome and also primary myofascial syndrome and articular dysfunction. Patients who were diagnosed as TOS were evaluated in two groups:

1. Patients suffering from serious vascular and neurological compression were defined ulnar nerve current velocity (UNCV) < 60 m/sn who had cervical rib. These patients were directly referred to surgery.
2. Patients, who were not treated with conservative therapy, who had UNCV > 60 m/sn, and who were not willing for surgical operation.

The patients in second group were first referred to physical therapy. The goal of physical therapy was to correct muscle imbalances and to increase neural mobility. Modification of behavior at home, work and sleep was necessary for long term relief of symptoms. Initially, treatment emphasized stretching the short tight muscles (upper trapezius, levator scapula, scalenes, sternocleidomastoid, pectoralis major/minor, suboccipitalis). The patients started their exercises in gravity-assisted positions to permit the appropriate recruitment of the weaker muscles. Most of our patients were treated before and after their hospitalization by anti-inflammatory and spasmolytic agents. The patients who benefited from physical therapy were not included in this study.

### 2.5. Surgery

Surgery was performed on patients for whom prolonged conservative treatment had failed and whose symptoms were reproduced by placing the brachial plexus on stretch and a significantly reduced UNCV (< 60 m/sn), and in the

patients with arterial or venous compression detected by doppler ultrasonography. When symptoms were acute or severe, early operation was indicated.

All our patients were operated by using the transaxillary approach. The preferred method for treating TOS was resection of the first-rib, fibrous ligaments, scalenectomy, and if present cervical rib. A transaxillary approach was performed for resection of the first-rib extraperiosteally. The incision was transaxillary below the hair line, and transverse between the pectoralis major muscle anteriorly and the latissimus dorsi muscle posteriorly. The incision was carried directly to the chest wall without angling up toward the first-rib. When the chest wall was encountered, the dissection was carried superiorly to the first-rib, identifying the intercostal brachial and thoracic longus nerve. It was preserved by retracting anteriorly or posteriorly. The medial scalene muscle and the intercostal muscle of the second-rib were then eased off the rib with elevators. Scalene muscles, fibrous ligaments, and costoclavicular ligament were resected. The first-rib with periosteally was resected near the costal cartilage anteriorly and the transverse process posteriorly or disarticulation, keeping the T1 root out of the operative field. Then, if there was cervical rib, it was completely resected. The pleura was inspected carefully to detect any tears. Pneumothorax could occur from a lesion in the parietal pleura, and a drain in the tear was inserted. The cervical spine was radiologically examined intraoperatively to assess the stump of the first-rib.

### 2.6. Follow-up evaluation

The cases who have no symptoms after the operation were classified as 'very good', those with a greater ratio of remission of symptoms were classified as 'good', and cases with no or little amelioration of symptoms were classified as 'bad'. Exercises were ordered for patients beginning in the early postoperative hours. All patients performed exercises at home, given by the physical therapy department, after being discharged. As medical therapy at least 2 weeks of anti-inflammatory treatment and a month long vitamin B6 treatment were given. Patients were evaluated periodically within 6 months. Patients were observed until their symptoms resolved or an additional intervention was performed; however there was no routine schedule of follow-up after 6 months.

### 2.7. Statistical analysis

The morbidity and numerical data relationship were evaluated using Fisher's exact test and the pre- and post-operative EMG values were evaluated using paired *t*-test and Student's *t*-test. A *p* value less than 0.05 was considered to be significant.

## 3. Results

Twenty-six of the cases were females (75%) and nine were males (25%). To 35 patients whose mean ages were  $25 \pm 1$  (17–40 years) a total number of 40 operations were performed. The most important symptom was localized pain (being in multiple sites in 60% of cases) 90% in the arm, 50% in the neck, 30% in the shoulder, and 20% in the head. In 20% of cases fatigue of the arm, in 30% coldness, in 10% atrophy, and in 20% cyanosis were present. In 30% of our cases (85%) paresthesia was present; 70% of these were in the ulnar nerve region (C8–T1) and 15% were in the median nerve region (C5–C7). In almost 90% of our patients the Adson's test, costoclavicular test, AER and the hyperabduction test were positive. There were no pathologies in the routine blood and biochemical tests. The EMG test results were consistent with TOS in only 65% of our cases. The preoperative EMG average values of our cases were found to be 56.71 m/s. The postoperative control EMG values were 65.19 m/s. Postoperative EMG values were significantly higher than the preoperative EMG values ( $p < 0.001$ ). In the venous and arterial doppler ultrasonographic examinations

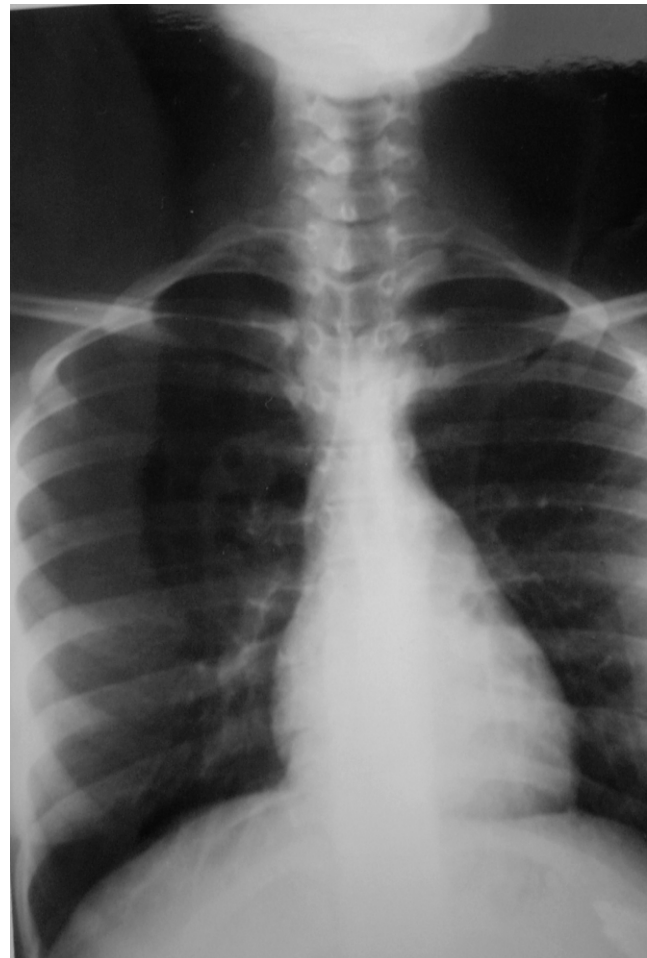

Fig. 1. The X-ray of the patient with a cervical rib.

performed using the Adson's test, three patients (9%) were found to have compression. Upon radiological investigation ( $n = 17$ ) 50% of the patients were found to have cervical ribs. Five of those were bilateral and 12 were unilateral (Fig. 1). Physical therapy was applied in 30 patients preoperatively (85%), but because the symptoms continued, they were referred to surgery. Since two of the other five patients had severe atrophy and three had apparent vascular compression leading to cyanosis in their arms, they were not given physical therapy preoperatively. All patients were operated on using the transaxillary approach. The first-rib and the fibrous bands and scalenius anticus-medius were excised in all patients. The excision of the first-rib has been performed without deperiostation. During this resection, care has been taken to avoid injuries to the phrenic nerve and the vascular structures. A total number of 40 operations were performed. Disarticulation of the ribs was carefully performed in both resections of the first-rib and the cervical ribs (Fig. 2). This was verified by palpation and intraoperative X-ray investigation (Fig. 3).

In 30 cases (85%) the results were very good and in four cases (12%) good, and in one case (3%) the results were bad. In one case who did not benefit from operation, the preoperative diagnosis was found to be inadequately made. The patient was found to have cervical discopathy.

In five cases (14%) complications developed. In three cases pneumothorax developed due to parietal pleural opening and in two patients hematomas developed. All of our patients were discharged with complete recovery. The average hospital stay was found to be 5 days (3–10 days).

Our patients had pain and numbness in various locations for the first 2 months postoperatively in their long term follow-up. Elevation of the scapula was observed in two cases around the 15th postoperative day. In our further observations this problem also resolved. In the second two monthly period no serious complaints were noted. About 20 cases could be followed for approximately 5 years.

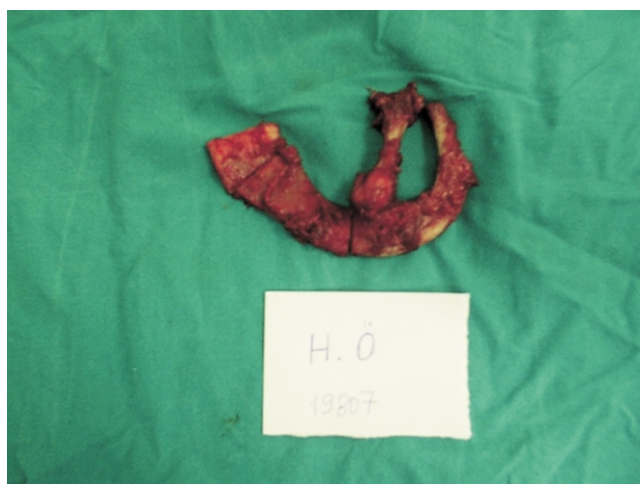

Fig. 2. The resection of the cervical rib with the first-rib.

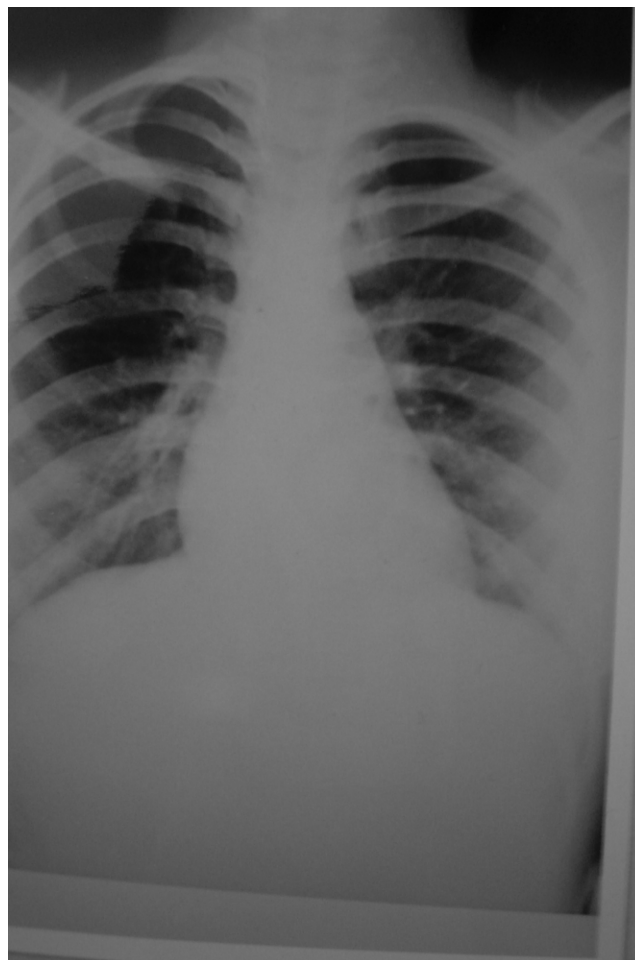


Fig. 3. Postoperative X-ray of the patient.

In this late postoperative period, at various times, especially after heavy work or upon encountering very cold weather, pain and numbness were reported. All these symptoms responded to medication. None of the cases were reoperated because of recurrence.

#### 4. Discussion

There are unilluminated points in the etiology and pathophysiology of TOS even though there have been improvements in the treatment and careful studies have been made about anatomical details. The presence of a cervical rib is not always clearly related to the syndrome. Since cervical ribs can be observed in 0.5–1% of the general population, only 10% of these patients presented with symptoms. Only 3–30% of TOS cases have cervical ribs [8]. This ratio is 50% ( $n = 17$ ) in our series. We think the reason for this is our selectivity in these kinds of cases. Another reason might be the fact that cases without cervical ribs are medically treated and those with cervical ribs are referred to other reference centers from hospitals in the periphery. We would

like our patients to undergo medical and physical therapy first if there was not a serious compression. Additionally another important point is the differential diagnosis for other ailments which may cause these symptoms. Furthermore there are fibromuscular ligaments in 98% of patients with TOS. These ligaments have been found to exist in 33% of cadavers not having TOS. These findings suggest a congenital predisposing reason for most TOS cases [9]. The emergence of symptoms upon the congenital predisposing factors in the second to third decade seems to be related to minor or major traumas, the pain-spasm vicious cycle, excessive muscular activity with myotendinitis and body posture. In fact TOS cases form two groups according to these reasons. The first group consists of the people with extensive muscle development in the arm and shoulder regions. The second group consists of asthenic people. The patients in the second group respond well to regulation of the upper thorax posture towards normal and physical therapy [10].

The narrowing of the thoracic aperture because of the above reasons, causes symptoms of TOS to appear. These symptoms are largely due to the compression of the brachial plexus. In 2–10% of the cases there is vascular compression [11]. This ratio is 10% in our series too. We should also emphasize the fact that we observe serious compression of the brachial plexus not detected in preoperative investigations in cases with predominant vascular compression. This might be explained, thanks to the anatomical structure. The adjacent brachial plexus has to be affected previously in order for the vascular structures in the thoracic aperture to be compressed. However, this condition might change in the presence of fibrous bands. The abovementioned condition is observed mostly in the presence of anomalous conditions of the first-rib and the presence of a cervical rib.

Although Caldwell et al. report that EMG measurements and nerve conduction speed are objective criteria as diagnostic tests in TOS this is unfounded in general [12]. It is generally accepted that nerve conduction velocities are significant in making the differential diagnosis between TOS and the carpal tunnel syndrome, cubital tunnel syndrome or other orthopedic shoulder and hand problems. In our series 65% of the cases were found to be consistent with TOS diagnosis. We also made a statistical analysis of EMG results. Postoperative EMG values were significantly higher than the preoperative EMG values ( $p < 0.001$ ). This shows that our patients were carefully selected and the compression was evident. Additionally in the differential diagnosis of TOS, cervical discopathy and spinal cord lesions should be taken into account too.

Primarily conservative treatment should be given to patients diagnosed as TOS. Patients with mild and moderate symptoms have a high chance of benefiting from physical therapy. This also gives the team of physicians an opportunity to give a clearer decision for cases that will be selected for surgery. But in cases with serious neurological and vascular compression there is no need to have primary conservative therapy. The most important point is the fact

that exercises should be started in the very early post-operative hours and continued for about 2 months. These applications will reduce adhesions and indirectly decrease relapses.

Some of the postoperative complications published in the literature are pneumothorax, wound infections and hematomas which can be easily cured. Others include injuries to the brachial plexus, the long thoracic nerve, the phrenic nerve and subclavian artery or vein [13]. If the pleura is punctured, drainage should be provided. In three of our cases (15%) the pleura was inadvertently opened. One of them was treated by primary suturing and the two others were treated by tube thoracostomy. The phrenic nerve has to be protected when the first costal cartilage part of the anterior scalene muscle is resected. The posterior part of the first-rib is either disarticulated or resected on the level of the transverse process. The rib should be removed without deperiostation. This is the main factor which will prevent ossification and relapse which might follow. If the posterior end is left long it may cause irritation of the root T1 or may lead to callus formation which may later cause pain. It should be remembered that the intercostal vein may be injured when the posterior end is being removed. Abnormal fibromuscular bands must be carefully sought for and excised during the operation. The first-rib cannot be entirely removed by the supraclavicular approach. Even if it is tried, because the joints cannot be disarticulated, the remaining bone tissue and the consequent callus development causing adhesions may cause relapses. In two of our patients dislocation of the scapula occurred about 15 days post-operatively. We thought that this might be due to excessive exercise. These complications resolved with conservative treatment. Morbidity was found to be higher in male patients ( $p < 0.05$ ). We explained this finding by the fact that male patients are anatomically more developed and their surgery was more difficult.

Success rates in the literature vary between 82 and 96%. In our series the 'very good' and 'good' results are 97%. We did not perform surgery to any patient for relapse. In the series reporting about results of transaxillary approach the success rate is given around 80% and the relapse rate is reported around 10–20% [14,15]. There is a cervical rib in 12% of patients with TOS in the literature. The highest reported ratio is around 30% [15]. In our cases there were cervical ribs in 17 patients (50%) five of which were bilateral. The fact that we emphasized bone anomalies is as important as the care in selecting patients for surgery is evident.

The transaxillary approach is the most cosmetic one among the operation techniques for TOS. The higher rate of females among TOS patients makes this statement more important.

## 5. Conclusion

1. As a result, careful patient history and physical

examination should be done by a team, which consists of thoracic surgeon, physical therapy specialist, and a neurologist. Especially diseases of the neck, shoulder, and arm should be carefully eliminated.

2. Patients suffering from serious vascular and neurological compression were defined UNCV <60 m/sn who had cervical rib. These patients were directly referred to surgery. But, patients, who were not treated with conservative therapy, who had UNCV >60 m/sn, and who were not willing for surgical operation were first referred to physical therapy. Most of these patients were treated by conservative therapy.
3. The surgical treatment of TOS depends on the removal of the first-rib and coexisting pathologies (cervical rib, fibrous ligaments, scalenius muscles).
4. The transaxillary approach has provided a good exposure for the resection of cervical ribs, the first-rib and excision of fibrous ligaments and scalenius muscle by a perfect cosmetic result.
5. All the patients should be encouraged for 2 months of physical exercises starting from early postoperative period.

## References

- [1] Roos DB. Historical perspectives and anatomic considerations. *Semin Thorac Cardiovasc Surg* 1996;8:183–9.
- [2] Rob CG, Standeven A. Arterial occlusion complicating thoracic outlet compression syndrome. *Br Med J* 1958;2:709–12.
- [3] Skandalakis JE, Mirilas P. Benign anatomical mistakes: the thoracic outlet syndrome. *Am Surg* 2001;67:1007–10.
- [4] Clagett OT. Presidential address: research and prosearch. *J Thorac Cardiovasc Surg* 1962;44:153–66.
- [5] Ross DB. Transaxillary approach for first-rib resection to relieve thoracic outlet syndrome. *Ann Surg* 1966;163:354–8.
- [6] Mackinnon SE, Patterson GA. Supraclavicular first rib resection and brachial plexus decompression for thoracic outlet syndrome. In: Rengachary SS, editor. *Neurosurgical operative atlas*. Baltimore, MD: Williams and Wilkins; 1993. p. 185–91.
- [7] Komanetsky RM, Novak CB, Mackinnon SE, Russo MH, Padberg AM, Louis S. Somatosensory evoked potentials fail to diagnose thoracic outlet syndrome. *J Hand Surg* 1996;21A:662–6.
- [8] Sanders RJ, Hammond SL. Management of cervical ribs and anomalous first-ribs causing neurogenic thoracic outlet syndrome. *J Vasc Surg* 2002;36(1):51–6.
- [9] Sheth RN, Belzberg AJ. Diagnosis and treatment of thoracic outlet syndrome. *Neurosurg Clin N Am* 2001;12(2):295–309.
- [10] Athanassiadi K, Kalavrouziotis G, Karydakis K, Bellenis I. Treatment of thoracic outlet syndrome: long-term results. *World J Surg* 2001;25(5):553–7.
- [11] Gelabert HA, Machleder HI. Diagnosis and management of arterial compression at the thoracic outlet. *Ann Vasc Surg* 1997;11:359–66.
- [12] Caldwell JW, Crane CR, Krusen EM. Nerve conduction studies: and aid in the diagnosis of the thoracic outlet syndrome. *South Med J* 1971;64:210–2.
- [13] Sharp WJ, Nowak LR, Zamani T, Kresowik TF, Hoballah JJ, Ballinger BA, Corson JD. Long-term follow-up and patient satisfaction after surgery for thoracic outlet syndrome. *Ann Vasc Surg* 2001;15(1):32–6.
- [14] Axelrod DA, Proctor MC, Geisser ME, Roth RS, Greenfield LJ. Outcomes after surgery for thoracic outlet syndrome. *J Vasc Surg* 2001;33(6):1220–5.
- [15] Fulford PE, Baguneid MS, Ibrahim MR, Schady W, Walker MG. Outcome of transaxillary rib resection for thoracic outlet syndrome—a 10 year experience. *Cardiovasc Surg* 2001;9(6):620–4.

**Transaxillary approach in thoracic outlet syndrome: the importance of resection of the first-rib**

Serdar Han, Erkan Yildirim, Koray Dural, Kanat Özisik, Rasih Yazkan and Ünal Sakinci

*Eur J Cardiothorac Surg* 2003;24:428-433

DOI: 10.1016/S1010-7940(03)00333-6

**This information is current as of July 14, 2009**

<b>Updated Information &amp; Services</b>	including high-resolution figures, can be found at: <a href="http://ejcts.ctsnetjournals.org/cgi/content/full/24/3/428">http://ejcts.ctsnetjournals.org/cgi/content/full/24/3/428</a>
<b>Subspecialty Collections</b>	This article, along with others on similar topics, appears in the following collection(s): <b>Peripheral vascular</b> <a href="http://ejcts.ctsnetjournals.org/cgi/collection/peripheral_vascular">http://ejcts.ctsnetjournals.org/cgi/collection/peripheral_vascular</a> <b>Chest wall</b> <a href="http://ejcts.ctsnetjournals.org/cgi/collection/chest_wall">http://ejcts.ctsnetjournals.org/cgi/collection/chest_wall</a>
<b>Permissions &amp; Licensing</b>	Information about reproducing this article in parts (figures, tables) or in its entirety can be found online at: <a href="http://ejcts.ctsnetjournals.org/misc/Permissions.shtml">http://ejcts.ctsnetjournals.org/misc/Permissions.shtml</a>
<b>Reprints</b>	Information about ordering reprints can be found online: <a href="http://ejcts.ctsnetjournals.org/misc/reprints.shtml">http://ejcts.ctsnetjournals.org/misc/reprints.shtml</a>

EUROPEAN JOURNAL OF  
**CARDIO-THORACIC**  
**SURGERY**